

Acute and Sub-Chronic Oral Toxicity Studies of an Aqueous Extract of *Hallea stipulosa* (Rubiaceae) in Wistar Rats

Poualeu Kamani S L^{1*}, Wansi S L¹, Mzoyem N J¹, Miaffo D^{1,2}, Nkeng-Efouet A P³,
Kamanyi A¹

¹Laboratory of Animal Physiology and phytopharmacology, department of Animal Biology, Faculty of Sciences, University of Dschang, Cameroon.

²Laboratory of Department of Life and Earth Sciences, Higher Teacher's Training College, University of Maroua, Cameroon.

³Department of Chemistry, University of Dschang, Cameroon.

Available Online: 10th August, 2016

ABSTRACT

Hallea stipulosa (Rubiaceae) is a Cameroonian medicinal herb traditionally used for the treatment of various ailments including diabetes, hypertension, diarrhea, and gastric ulcer. To determine safety margin from the use of this plant, acute and sub-chronic toxicity studies of the stem bark aqueous extract of *Hallea stipulosa* (AEHS) were performed in rats. In acute toxicity, single oral administration 2000 mg/kg or 5000 mg/kg of AEHS caused neither toxicological symptoms nor mortality and the LD₅₀ was estimated > 5000 mg/kg. In the sub-chronic oral toxicity, no significant variation in body weight and food intake was observed in treated animals compared to the control group. Water consumption decreased at 100 and 200 mg/kg, suggesting inhibitory effects of the extract on hypothalamic osmoreceptors that regulate thirst. No significant change in blood glucose, hematological parameters, total and direct bilirubin was observed. A reduction in the relative kidney weight was observed at 200 mg/kg. A reduction of serum levels of ALT, AST and protein was observed at 50, 100 and 200 mg/kg. The decrease in protein levels could reflect kidney dysfunction which would have resulted in the decline in the relative kidney weight. Histological analysis revealed no abnormalities in the structure and morphology of the heart, pancreas and kidneys. However, vascular congestion was observed on the histology of the liver at 100 and 200 mg/kg. The results indicate a broad safety margin of AEHS; however, any repeated use at higher doses exposes to liver and kidney impairments.

Keywords: *Hallea stipulosa*, acute toxicity, sub-chronic toxicity, rats.

INTRODUCTION

Herbal medicine or phytomedicine is recognized as the most common form of alternative medicine¹. According to the estimations of Rates² and Grover and Yadav³, more than 80 % of Africa's populations still use traditional medicine to meet their needs for health care. Herbal drugs which are commonly used in traditional medicine are frequently promoted as "natural" and; therefore, harmless^{4,5}. However, some medicinal plants must be used with caution since they can be potentially harmful at high doses and can interact with modern drugs⁶. Therefore, it has become imperative to ascertain the toxicity profile of these medicinal herbs. *Hallea stipulosa* (HS) is a medicinal plant whose stem bark decoction are used in traditional medicine especially in West and South regions of Cameroon to treat many diseases such as diabetes, diarrhea, cancer and hypertension⁷. In spite of its therapeutic potentials, toxicity studies of the stem bark of this plant is scanty. The present work then aimed at evaluating the possible toxic effects of the stem bark AEHS after acute and sub-chronic oral administrations in male and female Wistar rats.

MATERIALS AND METHODS

Plant material

The stem bark of *Hallea stipulosa* was collected in Fouban- Cameroon in June 2013. The plant was identified and authenticated at the Cameroon National Herbarium in comparison with the reference voucher specimen number 21076/ SRF/ CAM. The stem bark of HS was then air dried at room temperature and ground into a fine powder.

Aqueous extract preparation

One Kilogram (1kg) of the dried powdered plant was boiled in 5 liters of distilled water for 20 minutes. The decoction cooled at room temperature, was then filtered. The filtrate was concentrate by evaporating water at 40°C in a drying oven for 48 hours to afford. 43.93 g of the aqueous extract (a 4.39 % yield) named AEHS.

Animals

Young adult male and female Wistar rats (weighing 150 ± 20 g) were used in this study. They were segregated according to the gender and then bred and housed in the animal house of the Laboratory of Animal Physiology and

*Author for Correspondence: sylviane.poualeu@univ-dschang.org

Table 1: Effect of the extract on biochemical profile of the rats after 28 days of subchronic toxicity study.

	GPI	GP II	GP III	GP IV
ALT	29.92 ± 2.24	20.49 ± 1.67	18.33 ± 1.96**	16.98 ± 1.08**
AST	78.93 ± 3.00	70.41 ± 3.58	54.67±4.07***	55.64±1.10***
Conjugated Bilirubin	0.21 ± 0.06	0.33 ± 0.07	0.37 ± 0.07	0.26 ± 0.08
Total Bilirubin	0.69 ± 0.07	0.89 ± 0.12	0.96 ± 0.20	0.84 ± 0.12
Total Protein	75.17 ± 0.90	69.13 ± 1.74	71.90 ± 2.84	60.94 ± 4.49*
Glucose	72.25 ± 2.76	67.25 ± 3.3	69.50 ± 2.74	68.63 ± 2.51

*P <0.05, **P <0.01, ***P <0.001 vs control. n=8; data are presented as mean ± SEM

Table 2: Effect of administration of AEHS on some hematological parameters in rats.

Parameter	Control	50 mg/kg	100 mg/kg	200 mg/kg
WBC (10 ⁹ /L)	6.23 ± 0.5	6.3 ± 0.35	5.83 ± 0.39	6.2 ± 0.67
RBC (10 ¹² /L)	6.39 ± 0.29	6.3 ± 0.5	6.55 ± 0.36	6.49 ± 0.27
PLT (10 ⁹ /L)	635.5 ± 26	619.67 ± 70.84	640.09 ± 49.5	603.67 ± 59.8
Lymphocytes (%)	63.07 ± 1.49	59.94 ± 2.52	58.08 ± 3.24	58.66 ± 2.52
Granulocytes (%)	35.5 ± 3.5	37.88 ± 2.85	39.17 ± 3.02	38.43 ± 4.53
Monocytes (%)	1.43 ± 0.12	2.19 ± 0.66	2.75 ± 0.91	2.91 ± 0.37
HGB (g/dl)	13.19 ± 1.6	13.27 ± 0.12	14.2 ± 1.11	14.15 ± 1.11
HTC (%)	44.84 ± 2.48	42.32 ± 0.96	48.18 ± 2.68	46.4 ± 2.88
PCV (f/L)	53.8 ± 1.45	53.34 ± 2.13	52.33 ± 1	52.99 ± 2.37
MCH (p/L)	16.75 ± 0.3	16.65 ± 0.57	16.38 ± 0.38	16.39 ± 1.16
MCHC (g/dl)	31.23 ± 0.33	31.29 ± 0.77	30.48 ± 1.16	31 ± 2.22
MPV	8.53 ± 0.13	8.59 ± 0.29	8.52 ± 0.22	8.41 ± 1.52
RDW (%)	17.45 ± 0.95	17.66 ± 1.2	16.97 ± 1.37	16.48 ± 1.99

n=8; data are presented as mean ± SEM

Phytopharmacology of the University of Dschang/Cameroon, at room temperature, with adequate ventilation and under a naturally illuminated environment. The animals were given food and water *ad libitum*, but fasted overnight prior to oral administration of the extract. Housing of animal and all the experiments were carried out following the guidelines of Zimmerman⁸.

$$\text{ROW} = \frac{\text{Absolute organ weight (g)}}{\text{Body weight of rat on day of sacrifice (g)}} \times 100$$

Acute toxicity of the extract

To study any possible toxic effect by single administration of an AEHS, Organization for Economic Co-operation and Development (OECD) guideline was used⁹. Twenty-four rats (12 males + 12 females) were fasted overnight (12h) with free access to water prior to the administration of distilled water for group I (n= 4 males and 4 females) and singles doses (2000 mg/kg and 5000 mg/kg) of the AEHS for groups II and III respectively. The general behavior of the rat was continuously monitored for 4h after treatment, then over a period of 24h and thereafter during 14 days. The lethal dose (LD 50) was estimated.

Sub-chronic toxicity

Thirty-two rats (150 – 180 g) were divided into four groups of 8 animals (4 males + 4 females). The first group, serving as control, received distilled water. Groups II, III and IV received 50, 100 and 200 mg/kg of AEHS, respectively. Treatments were orally administered for 28 consecutive days. During the treatment period, a daily record of rat body weight, the amount of feed and water intake was performed to determine the body weight profile, food and water consumptions.

Collection of blood and organ samples

At the end of the treatment period, rat glycemia was measured into blood obtained by incision of the tail using Accu-Chek Active glucometer, after a 12h overnight fasting. After a slight anesthesia (10 mg/kg diazepam and 50 mg/kg ketamin i.p), blood samples were collected from each rat by the catheterization of the abdominal artery into ethylenediaminetetraacetic acid (EDTA) tubes for hematological analysis and tubes without anticoagulant for biochemical analysis.

Following blood collection, a number of organs (heart, liver, pancreas, lung, spleen and kidney) were quickly removed, cleaned with saline solution (0.9%) and weight for calculation of relative organ weight (ROW). Organ samples (Heart, kidney, pancreas and liver) were next fixed in 10% formalin for histopathological examinations.

Hematological parameters

White blood cell (WBC), red blood cell (RBC) and platelets (PLT) counts, lymphocytes, granulocytes and monocytes percentage, hemoglobin (HGB), hematocrit (HTC), packed cell volume (PCV), mean corpuscular hemoglobin (MCH), mean corpuscular hemoglobin concentration (MCHC), mean platelet volume (MPV), and red blood cell distribution width (RDW), were determined using fully automated hematology analyser (PCE-210N).

Biochemical parameters

Blood samples in dry tubes were centrifuged at 3000 rpm for 15 min. Serum was separated and stored at – 20 °C until determination of alanine aminotransferase (ALT) and aspartate aminotransferase (AST) according to the colorimetric method described by Reitman and Frankel¹⁰, total protein according to the methods described by Gornall et al.¹¹ and total and direct bilirubin by using semi-

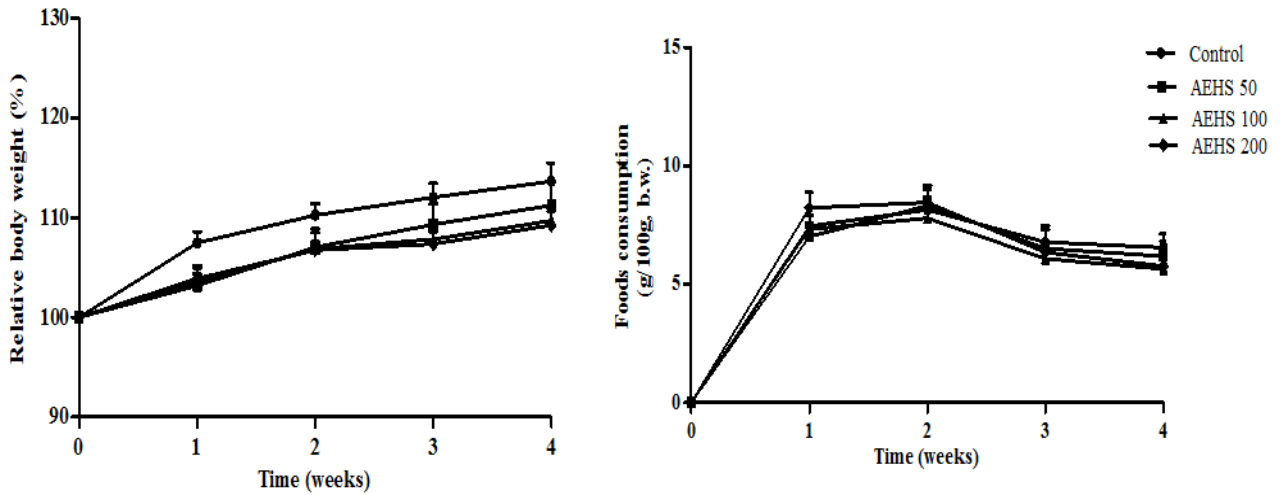


Figure 1: Body weight and food consumption of rats treated with *Hallea stipulosa* (HS) for 28 consecutive days. AEHS 50: aqueous extract of HS at dose 50 mg/kg; AEHS 100: aqueous extract of HS at dose 100 mg/kg; AEHS 200: aqueous extract of HS at dose 200 mg/kg. n=8; data are presented as mean \pm SEM.

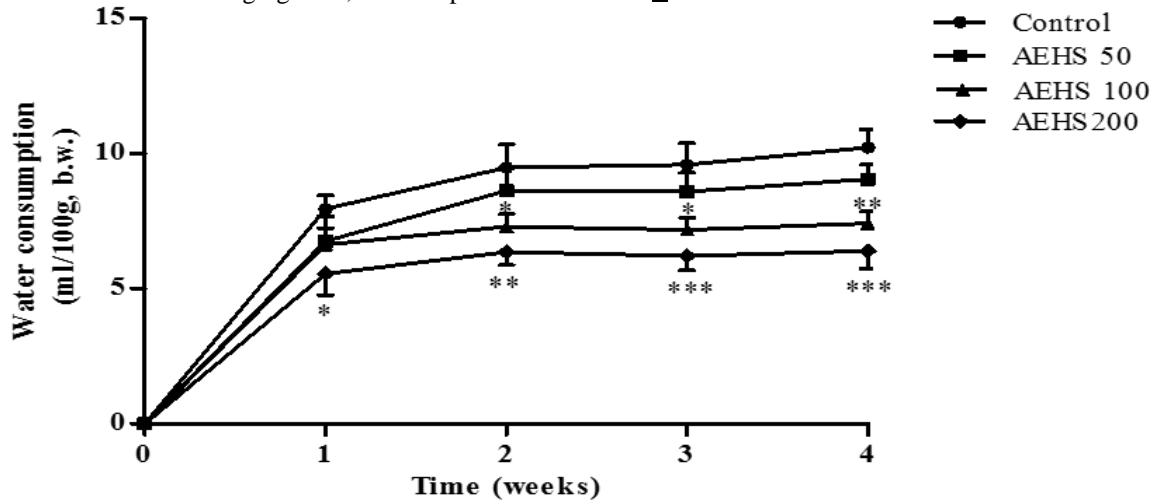


Figure 2: Water consumption of rats treated with HS (50-200 mg/kg) for 28 consecutive days. AEHS 50: aqueous extract of HS at dose 50 mg/kg; AEHS 100: aqueous extract of HS at dose 100 mg/kg; AEHS 200: aqueous extract of HS at dose 200 mg/kg. *P < 0.05, **P < 0.01, ***P < 0.001 vs control. n=8; data are presented as mean \pm SEM.

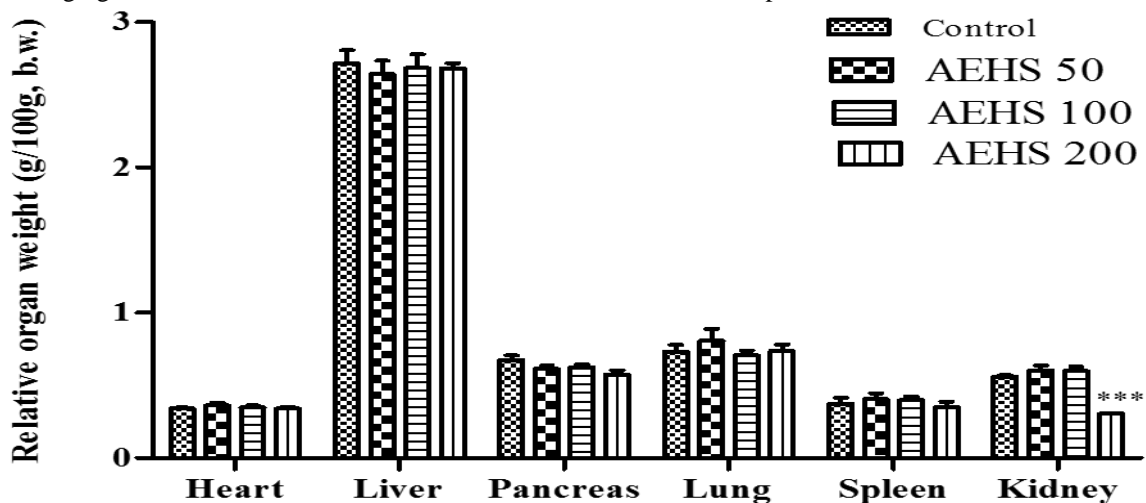


Figure 3: Effects of the AEHS on the relative organ weight of rats after 4 weeks of oral dosing. AEHS 50: aqueous extract of HS at dose 50 mg/kg; AEHS 100: aqueous extract of HS at dose 100 mg/kg; AEHS 200: aqueous extract of HS at dose 200 mg/kg. ***P < 0.001 vs control. n=8; data are presented as mean \pm SEM.

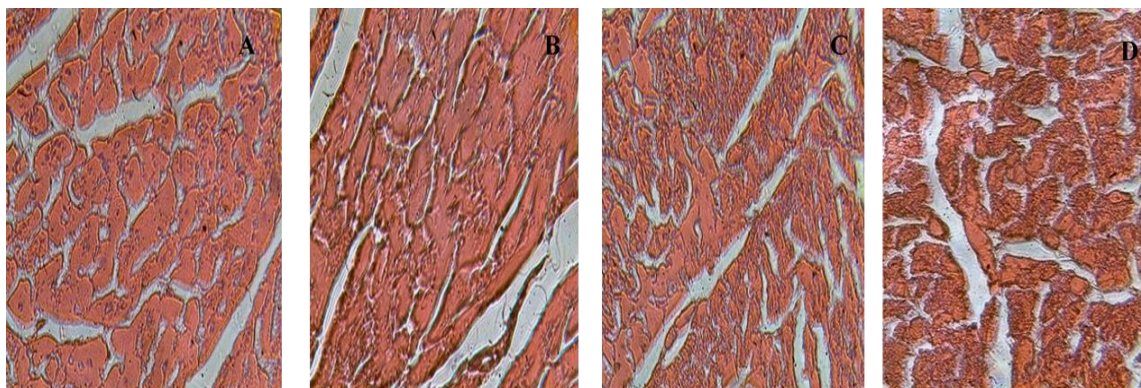


Figure 4: Micrographs of the heart sections following a 28-day treatment. No change in all the treated groups. (a) control. (b) Rats treated with AEHS at 50 mg/kg bw. (c) Rats treated with AEHS at 100 mg/kg bw. (d) Rats treated with AEHS at 200 mg/kg bw. 400X, H/E, 5 μ m.

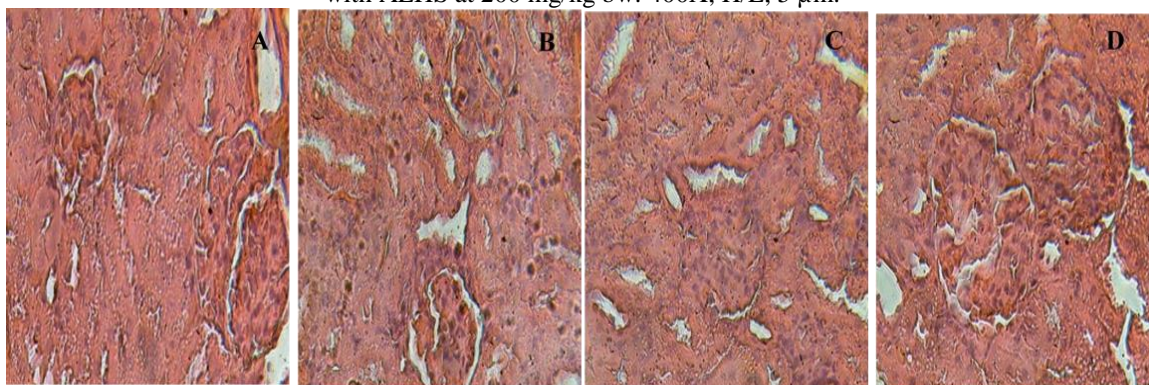


Figure 5: Micrographs of kidney sections following a 28-day treatment. No change in all the treated groups. (a) control. (b) Rats treated with AEHS at 50 mg/kg bw. (c) Rats treated with AEHS at 100 mg/kg bw. (d) Rats treated with AEHS at 200 mg/kg bw. 400X, H/E, 5 μ m.

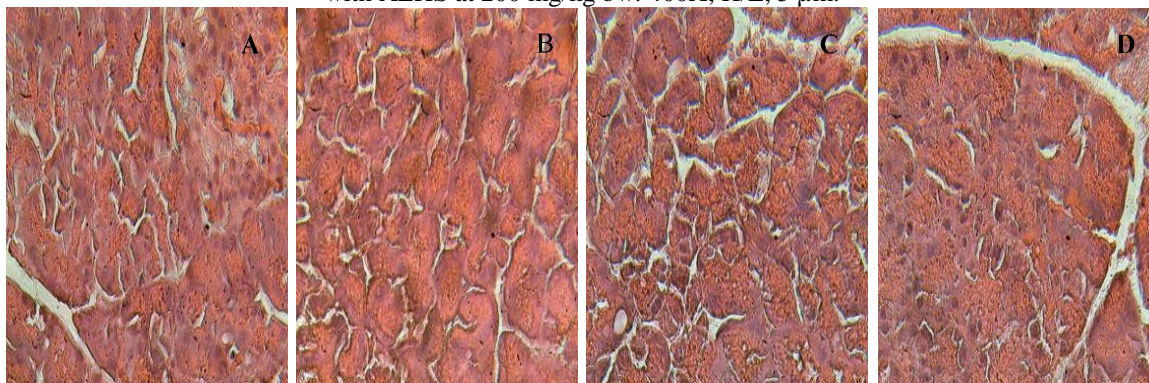


Figure 6: Micrographs of pancreas sections following a 28-day treatment. No change in all the treated groups. (a) control. (b) Rats treated with AEHS at 50 mg/kg bw. (c) Rats treated with AEHS at 100 mg/kg bw. (d) Rats treated with AEHS at 200 mg/kg bw. 400X, H/E, 5 μ m.

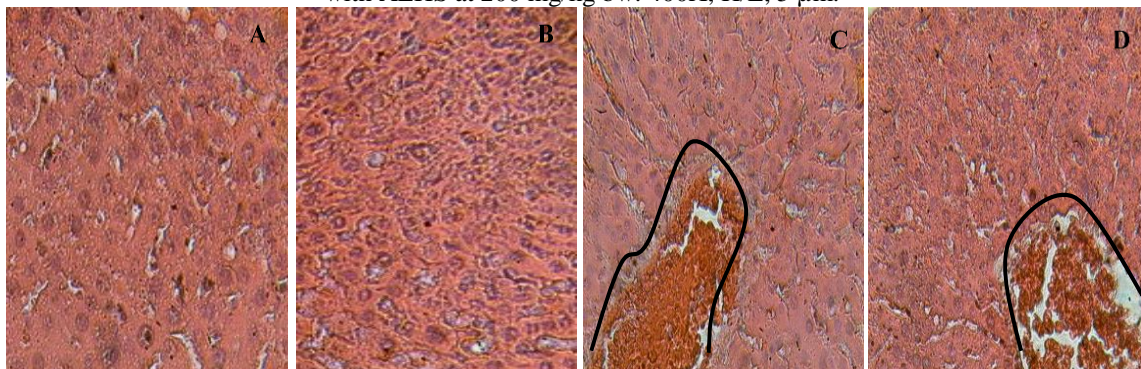


Figure 7: Micrographs of liver sections following a 28-day treatment. Vascular congestions at 100 and 200 mg/kg. (a) control. (b) Rats treated with AEHS at 50 mg/kg bw. (c) Rats treated with AEHS at 100 mg/kg bw. (d) Rats treated with AEHS at 200 mg/kg bw. 400X, H/E, 5 μ m.

automatic biochemical analyser (AE-600N, ERMA.Tokyo).

Histopathology

The fixed organs were macroscopically sectioned, dehydrated by serial increasing degree of ethanol solution and embedded with paraffin. The micrometer sections were cut by a microtome in 3-5 μ m slices and stained with haematoxylin and eosin. The slides were examined under a light microscope.

Statistical analysis

Results were expressed as mean \pm standard error of the mean (SEM). Data obtained were analyzed by using one way or two ANOVA followed by Turkey's and Bonferroni' tests respectively using Graph pad Prism Version 5.0; the p values < 0,05 were considered significant.

RESULTS AND DISCUSSION

Acute oral toxicity study

The administration of a single oral dose of AEHS 2000 and 5000 mg/kg induced neither mortality nor treatment-related signs of toxicity in animals throughout the observation period (14 days), indicating a lethal dose 50 (LD₅₀) greater than 5000 mg/kg bw. There are various studies on LD₅₀ determination of plant extract which report that substances with LD₅₀ higher than 5000 mg/kg via oral route may be considered practically non toxic^{12,13}. Therefore, the observations from acute toxicity studies suggest that AEHS is relatively nontoxic.

Sub-chronic oral toxicity study

Effects of AEHS on body weight, water and food intake

Changes in body weight and food intake have been used as indicators of adverse effects of drugs and chemicals¹⁴. There was no significant variation in food intake and body weight of treated rats compared to control rats (figure1), suggesting that AEHS did not suppress appetite and consequently did not alter animal growth. Figure 2 shows that water consumption significantly decreased in animals treated with AEHS at 100 and 200 mg/kg throughout the study, suggesting a decrease in the activity of hypothalamic osmoreceptors which are known to regulate thirst¹⁵.

Effects of AEHS on relative organ weight

No significant change on relative organ weights was noticed except in group IV, in which a significant decrease (p < 0.001) in kidney weight was observed (figure 3); According to Suon-Savich¹⁶, a reduction of the kidney weight may result from an impaired renal function, reducing water lost and consequently thirst feeling.

Effects of AEHS on biochemical and hematological parameters

The effect of sub-chronic administration of AEHS on biochemical and hematological parameters are presented on tables I and II respectively. According to Olson et al.¹⁷, analysis of blood parameters is relevant to risk evaluation as change in the hematological system have a higher predictive value for human toxicity, when data are translated from animal studies. Results revealed no significant change in the total bilirubin, conjugated bilirubin and glucose level when compared to the control

group (Table1). Bilirubin is the end product heme breakdown¹⁸. About 80 % of bilirubin originates from degradation of erythrocyte hemoglobin in the reticuloendothelial system; the remaining 20 % comes from inefficient erythropoiesis in bone marrow and degradation of other heme proteins^{19,20}. This suggests that AEHS might not promote the degradation of red blood cells. Serum ALT levels significantly decreased at all tested doses while AST levels were found decreased at 100 and 200 mg/kg (table 1). ALT and AST are considered marker for liver function²¹. The reduction of serum concentration of ALT and AST clearly suggests a hepatoprotective action of AEHS. Likewise, a significant decrease (p < 0.05) of total serum proteins was observed in group IV (table 1). Accordind to Djami et al.²², the reduction in total proteins can suggest a liver disorder, a kidney disorder or a disorder in which protein is not digested or absorbed properly. AEHS might cause renal dysfunction resulting in reduction of the relative weight of the kidney. The hematopoietic system is one of the most sensitive targets for toxic compounds and an important index for physiological and pathological status in man and animal²³. No significant difference in all the assessed parameters was observed following treatments (table II). This indicated that AEHS is not able to produce toxic effects on the hematopoietic system.

Results from the histological analysis

Microscopic examination of the heart, kidneys and pancreas in all treated groups did not revealed any structural changes following treatments (Figures 4, 5 and 6). However, the histopathological study of the liver (Figure 7) indicated a slight congestion in groups treated with the highest tested doses of AEHS. According to Mshelia et al.²⁴, congestion of blood vessels usually results from vascular abnormality such as venous obstruction; this suggest that highest doses of AEHS probably caused impair venous outflow in rats' liver and thus lead to congestion.

CONCLUSION

The stem bark aqueous extract of *Hallea stipulosa* was practically nontoxic in rats after acute oral administration (LD₅₀ > 5000 mg/kg). However, the extract may have deleterious effects on the liver and kidney at high doses following long term administration. These findings support its safe ethno medicinal use at moderate doses.

ACKNOWLEDGEMENTS

The authors are grateful to Drs Chouna for the extraction of the plant material and Mvondo Marie Alfrede for providing facilities and encouragements.

REFERENCES

- Ogbonnia SO, Mbaka GO, Anyika EN, Emordi JE, Nwakakwa N. An evaluation of acute and sub-chronic toxicities of a Nigerian polyherbal tea remedy. Pakistan journal of nutrition 2011; 10 (11): 1022-28.
- Rates SM. Plants as source of drug. Journal of Toxicon 2001; 39 (5): 603-613.

3. Grover JK, Yadav SP. Pharmacological actions and potential uses of *Momordica charantia*: a review. *Journal of Ethnopharmacology* 2004; 93(1): 123-32.
4. Rahma A, Choudhary MI. Recent Studies on Bioactive Natural Products. *Pure and Applied Chemistry* 1999; 16: 1079-1081.
5. Bnouham M, Merhfour FZ, Elachoui M. Toxic Effects of Some Medicinal Plants Used in Moroccan Traditional Medicine. *Moroccan Journal of Biology* 2006; 2: 21-30.
6. Inamul H. Safety of Medicinal Plants. *Pakistan Journal of Medicinal Research* 2004; 43:4.
7. Nyemb et Nyumäi. *Mitragyna stipulosa* (DC) kuntze. *Prota* (2): Timbers Bois d'œuvre 2. 2011; 10p.
8. Zimmerman M. Ethical guidelines for investigation of experimental pain in conscious animal. *Pain* 1983; 16 (2): 109-110.
9. Oecd. Oecd guidelines for the testing chemicals. *Acute oral Toxicity-Up-and-Down-Procedure (UDP)* 2008. Test No 425; 27p.
10. Reitman S, Frankel S. Glutamic-pyruvate transaminase assay by colorimetric method. *American Journal of Clinical Pathology* 1957; 28:56.
11. Gornall AG, Bardwil G, David MM. Determination of serum proteins by mean of Biuret reactions 1949. *Biochemistry*; 177: 751-756.
12. Donkor K, Okine LNK, Abotsi WKM, Woode E. Acute and sub-chronic toxicity studies of aqueous extract of root bark of *Cassia sieberiana* (DC) in rodents. *Journal of Applied Pharmaceutical science* 2014; 4(4): 84-89.
13. Singh AK, Attrey DP, Deep P, Dubey S, Naved T, Roy B. Acute and sub-acute toxicity studies of pharmacologically active *Seabuckthorn* leaf extract. *International Journal of Pharmacy and Pharmaceutical Sciences* 2014; 6(6): 415-419.
14. Mukinda JT, Eagles PFK. Acute and sub-chronic oral toxicity of the aqueous extract of *Polygala fruticosa* in female mice and rats. *Journal of Ethnopharmacology* 2010; 128: 236-240.
15. Wansi SL, Nguenefack-Mbuyo EP, Nchouwet LM, Miaffo D, Nyadjeu P, Wabo JP, Mbiantcha M, Nkeng-Efouet PA, Nguenefack TB, Kamanyi A. Antidiarrheal activity of aqueous extract of the stem bark of *Sapium ellipticum* (Euphorbiaceae). *Tropical Journal of Pharmaceutical Research* 2014, 13(6): 929-935.
16. Suon-Savich. La déshydratation du sujet âgé. Thèse de DIU de Médecin coordonnateur de l'Université René Descartes-Paris V, France 2011. 20p.
17. Olson H, Betton G, Robinson D, Thomas K, Monro A, Kolapa G, Lilly P, Sander J, Sipes G, Bracken W, Dorato M, Van Deun K, Smith P, Berger B, Heller A. Concordance of the toxicity of pharmaceuticals in human and in animals. *Regulatory Toxicology and Pharmacology* 2000; 32: 56-67.
18. Sticova E, Jirsa M. New insights in bilirubin metabolism and their clinical implications. *World Journal of Gastroenterology* 2013; 19(38): 6398-6407.
19. Stadel G. *Über die Farbstoffe der Galle*. *Anaalen d Chemie u Pharmacie* 1864; 132: 323-354.
20. Tenhunen R, Marver HS, Schmid R. The enzymatic conversion of heme to bilirubin by microsomal heme oxygenase. *Proceedings of the National Academy of Sciences of the United States of America* 1968; 61: 748-755.
21. Hilaly J, Ellsraili ZH, Lyoussi B. Acute and chronic toxicological studies of *Ajugaiva* in experimental animals. *Journal of Ethnopharmacology* 2004; 91: 43-50.
22. Djami TAT, Asongalem EA, Nana P, Choumessi A, Kamtchouing P, Asonganyi (). Subacute toxicity study of the aqueous extract from *Acanthus montanus*. *Electronic Journal of Biology* 2011; 7 (1): 11-15.
23. Mukunda JT, Since JA. Acute and chronic toxicity of the aqueous extract of *Artemisia afra* in rodents. *Journal of Ethnopharmacology* 2007; 112(1): 138-144.
24. Mshelia IY, Dalori BM, Hamman LL, Garba SH. Effect of the aqueous root extract of *Urena lobata* (Linn) on the liver of Albino rat. *Research Journal of Applied Sciences, Engineering and Technology* 2013; 5(1): 01-06.