

## Alafia Barteri is Associated with Increased Cd4 Cell Counts and Distortion of the Nephrons in Male Wistar Rats

Olatayo Segun Okeniran<sup>1\*</sup>, Olusola Atilade Adeeyo<sup>3</sup>, Aderonke Opeyemi Adeyemi<sup>4</sup>, Fred Ssempijja<sup>1</sup>, Salihu Mariama<sup>2</sup>, Ibe Michael Usman<sup>1</sup>, Olamide Adewale Adesanya<sup>1</sup> and Ojewale Abdulfatai Olakunle<sup>1</sup>

<sup>1</sup>Department of Human Anatomy, Faculty of Basic Medical Sciences, Mc Pherson University, Nigeria

<sup>2</sup>Department of Biochemistry, Faculty of Biomedical Sciences, Kampala International University Uganda

<sup>3</sup>Department of Anatomy, Faculty of Basic Medical Sciences, Federal University of Oye Ekiti Nigeria

<sup>4</sup>Department of Anatomy, Faculty of Basic Medical Sciences, Ladoke Akintola University of Technology Nigeria

\*Corresponding Author: Olatayo Segun Okeniran, Department of Human Anatomy, Faculty of Basic Medical Sciences, Mc Pherson University, Nigeria.

Received: May 18, 2022 Published: June 16, 2022

### Abstract

*Alafia barteri* Oliver (Hook F. Icon: Apocynaceae) is used in African traditional medicine on various ailments with pharmacological potential, information on the immunological and toxic effects remain scarce. This study establishes immunological and toxic effects of the ethanol *Alafia barteri* extract in male Wistar rats. An ethanol *Alafia barteri* leaf extract was prepared using previous standard methods by Solanki & Nagori 2012; Sunmonu & Afolayan 2013. The Wistar rats were divided into three groups (n= 5). Group I (control) received 2 mL of distilled water; Group II, III received 200, 300 mg/kg extract respectively for five weeks. The body and kidney weights, CD4 count, serum creatine and urea, kidney histology were analyzed using standard protocols. 4% and 6% of the LD50 showed significant increase in CD4 count (P< 0.0001) with 15.26 ± 1.477 cells/mm<sup>3</sup> (control) compared to 28 ± 1.283, and 95.48 ± 1.197 cells/mm<sup>3</sup> in the 4% and 6% doses respectively, in a dose-dependent manner (P< 0.0001). There were no significant changes (P> 0.05) in body and kidney weights, serum creatine, and urea. Histologically, 200 mg/kg of the extract was associated with dilatation while 300 mg/kg led to shrinkage in the nephrons. The extract was associated with CD4 cell numbers and osmotic histomorphology changes in the nephrons, with no evidence of changes in organ and bodyweights, serum creatinine, and urea. The findings strengthen opinions that plant extracts can be harmful to the kidneys and that Apocynaceae can modulate immunity.

**Keywords:** Apocynaceae; Body weight; Kidney weight, Kidney function; Kidney function tests; Urea, Creatinine, CD4 cells, Kidney histology, Immunology

### 1. Introduction

*Alafia barteri oliver* of the family *Apocynaceae* is a tropical rain forest plant, native to West and West-central tropical African countries such as Nigeria, Ghana, Liberia, Ivory Coast, Togo, Benin, Cameroon, Guinea Bissau, Congo and Gabon and a few East African countries such as Uganda, Kenya and South Sudan (Hamid et al., 2017; Lasisi et al., 2016; Sosef, 2006). The phytochemical constituents of *Alafia barteri* leaves and roots include total polyphenols, flavonoids, tannins, saponins, alkaloids, terpenoids, reducing sugar, steroids, glycosides, and anthraquinones (Hamid et al., 2017; Lasisi et al., 2016). The acute and sub-acute toxicity screenings of the plants are vital to determine the toxicological profiles of any herbs to authenticate their safety and harmful potential towards the consumers, yet only a limited number of medicinal plants have been screened for the same in Africa (Teke & Kuete, 2014). Evaluation of the intrinsic toxic effect of *Alafia barteri oliv* is important to know the safe preparations of phytotherapy of the plant and during drug development (Lasisi et al., 2016), and despite their numerous medicinal uses, the *Alafia barteri* plants have toxic compounds to human health such as pro-toxic dehydropyrolizidine alkaloids (Colegate et al., 2016; Liu et al., 2013). The ethanolic extract of the leaves from the plant is moderately toxic to the brine shrimp larvae (*Artemia salina*) with an LD<sub>50</sub> of 313-327 ppm (Lasisi et al., 2016), in some instances the oral ingestion of the extract is not associated with disruption of the physiology of structures and improves their function as was observed in the testes where their structure was not damaged, improved the sperm quality and increased the steroid hormones in *Wistar* rats (Adelakun et al., 2018).

A previous study demonstrated that there was no gain or loss of body weight associated with 500mg/kg body weight aqueous extract-treatment with *Alafia barteri* in rats for 4 weeks (S. Adelakun et al., 2018); another study showed an increase in the body weight associated with ingestion of 400mg/kg body weight of the aqueous extract for 6 weeks (Atilade et al., 2018, 2019).

Plant extracts have beneficial effects in certain diseases involving kidney pathology such as diabetic nephropathy, these are associated with reduced renal function. On the other hand, other plant extracts may be harmful to the kidneys leading to impairment of renal function in these disease conditions (Musabayane, 2012). Because herbal plants can take up toxic compounds such as heavy metals (Ssempijja et al., 2020), pro-toxic alkaloids (Colegate et al., 2016; Liu et al., 2013), and when consumed raw the herbs could pose major health risks to mammals (Ssempijja et al., 2020) including injury to the kidneys and renal failure (Olujimi et al., 2014). Renal cytochromes P450 and peroxidases are involved in the metabolism and activation of phytochemicals such as alkaloids (ellipticine) in *Apocynaceae* during treatment of ailments. Therefore the pharmacological efficiency, genotoxic side-effects, and excretion of these herbs (*Apocynaceae*) are dependent on the integrity of kidneys, and vice versa in rats, mimicking the fate of the herb in humans (Stiborova et al., 2010). A previous study involving oral ingestion of 500mg/kg aqueous extract of *Alafia barteri* in *Sprague Dawley* rats showed no toxicity to the gross morphology and histology of kidney cortex, indicating that the herb does not interfere with the kidney functions (S. Adelakun et al., 2018). Similar findings were observed with 400mg/kg body weight of the aqueous extract that was not toxic to the renal histological architecture in the normal and improved the histology of structures within the renal cortex of diabetic *Wistar* rats (Atilade et al., 2018).

Blood creatinine and urea are the most widely used indirect markers of kidney function. Elevated blood urea and creatinine levels signify impaired kidney function or kidney disease (Yadav et al., 2014). A previous study to determine the effect of ethanolic extract of a different variety (*Rauwolfia vomitoria*; *Apocynaceae*), from that used in our study (*Alafia barteri*; *Apocynaceae*), was associated with impaired renal biochemical indices (elevated serum creatinine and urea) attributed to a poor kidney function (Eteng et al., 2009), but even extracts from the same plant but different parts such as leaves and roots showed different effects on kidney function tests, and different varieties of the same family also gave rise to differences in the modulatory effect of the indices (Eteng et al., 2009; Musabayane, 2012).

Preparations of *Alafia barteri* roots, stems, leaves, and latex are used as in treatment as immune boosters through various pharmacological properties such as antispasmodic, antiplasmodial, antifungal, antibacterial, anti-inflammatory, reduction of edema, analgesia through inhibition of acetic acid, antiproliferative through cytotoxicity of cancer cells in rats (Hamid, Aiyelaagbe, Negi, et al., 2017; Sofidiya et al., 2014b), antiproliferative through suppressing the viability of the hepatic, breast and leukemic cancer cell lines (Hamid, Aiyelaagbe, Kaneez, et al., 2017), alkaloid inhibition of growth against human neoplastic cells (Liu et al., 2013), and antioxidation to protect cells and tissues against detrimental effects of reactive oxygen species and other free radicals (Owolabi et al., 2018). For example, because of its powerful antioxidant activity, *Alafia barteri* extract has been shown to have histo-protective effects on the cortex of the brain, heart, kidneys, liver, and testes in (S. Adelakun et al., 2018; Owolabi et al., 2018). The molecular mechanisms through which the medicinal herbs of African origin work to treat ailments have not been adequately determined (Mahomoodally, 2013), our study determined the effect of the extract on the health status of the immune system by measuring the CD4 count of *Wistar* rats. T-lymphocytes are leucocytes involved in cell-mediated immune responses of the innate and adaptive immune systems; CD4 cells are T-lymphocytes (T-helper cells) that protect the body by eliminating pathogens or preventing their growth (Li & Flavell, 2008). The functions of CD4 cells include the production of T-cell cytokines in response to specific antigen stimulation, help for antibody production, coordinating immune responses, lysis of virally infected target cells with type 2 histocompatibility antigens, serve as a cellular receptor for human immunodeficiency virus (HIV), and CD4-bearing lymphocytes are important target cells for HIV infection in the body. The CD4 cell count gives an indication of the health status of the immune system and the ability of the body to fight against pathogens, infections, and illnesses (Bodhade et al., 2011; Yarchoan et al., 1991). Treatment with an *Apocynaceae* herb variety (*Himatanthus drasticus*) has been shown to modulate CD4 cells in sarcoma bearing mice (Santos et al., 2018) and food supplements of *Apocynaceae* (*Aspidosperma subincanum* Mart. ex A. DC.) increased the CD4 count in HIV patients (Maes & Maes, 2015), findings of which are suggestive of the role of *Apocynaceae* in the improvement of the immune status of the body through CD4 cells during the management of certain ailments (Maes & Maes, 2015; Santos et al., 2018).

The objective of our study was to determine the effect of the ethanolic extract of *Alafia barteri* on the body weight, gross anatomy and histology of the kidney, kidney function, and CD4 cell count of male *Wistar* rats.

## 2. Methods

### 2.1 Study Design

This was an experimental study in which quantitative and qualitative data were collected from adult male *Wistar* rats kept in the animal house at Kampala International University, Western Campus. Fifteen (15) male *Wistar* rats (100-115 g) were randomly assigned based on weight into three experimental groups of 5 rats each.

Bodyweight experiments used adult animals at the age of 9 weeks and weighing 100-115 g at the start of the experiment; whereas experiments involving kidney morphology assessment, biochemical, hematological tests, and histology employed 13-week old rats weighing 105-135 g at the start of the experiments. Each rat was assigned a random number and the animals were then divided into 3 groups with each consisting of 5 rats (n= 5). Group I (control) rats were administered with 2ml of distilled water; Group II received 200mg/kg body weight; Group III got 300mg/kg bodyweight of *Alafia barteri* extract. The study design and animal models were used following previous methods by (Eteng et al., 2009; Sunmonu & Afolayan, 2013).

## 2.2 Data Collection Instruments

The body, kidney weight measurements and assessment of the gross morphology of the kidney were done using previous methods using an electronic weighing machine (Kent Scientific®) and visual inspection using unaided eyes, respectively (Atilade et al., 2018; Eteng et al., 2009; Hill et al., 2001). The kidney biochemical function tests were done using the Jaffe reaction for analysis of serum creatinine (Küme et al., 2017; Owen et al., 1954) and diacetyl monoxime for determination of blood urea (Marsh, 1964; Park, 1986). The CD4 cell count was obtained by flow cytometry using the cyflow automated cell counter (Ekaidem et al., 2010); histology of the kidney cortex was studied on photomicrographs stained with H and E and viewed under the Nikon Eclipse Ci, type 104c light microscope mounted to a Nikon digital sight DS Fi 1 camera to capture the images; a Toshiba computer connected to the couple was used to save the images, following previous methods (Ashburner, 1989; Fischer et al., 2008; Palladino et al., 2003).

## 2.3 Experimental methods

### 2.3.1 Plant material and authentication

Freshly picked *Alafia barteri* plant with mature fresh roots and leaves were obtained in January 2020 from a local bush within Ishaka-Bushenyi municipality, Western Uganda. A sample of the plant materials was taken for authentication by a Botanist (Dr. Olet Eunice) at the Department of Botany at Mbarara University of Science and Technology, Uganda; it was identified as *Alafia barteri* oliver of the family *Apocynaceae* and a voucher specimen (code No. LHO 407) was prepared and deposited at the Department of Anatomy, Kampala International University, Western Campus.

### 2.3.2 Preparation of the Ethanolic Extract of *Alafia barteri* oliver (*Apocynaceae*)

The extract was prepared using methods by (Solanki & Nagori, 2012) and (Sunmonu & Afolayan, 2013) briefly: the leaves plucked from the stalks were rinsed with distilled water, dried in an oven at 30°C. The dried leaves were slightly ground using a manual metallic mortar and pestle into fine powders that were kept in air-tight glass containers. The ethanolic extract of the plant was prepared by soaking 200g of the powdered sample in 2L of 96% ethanol in an Erlenmeyer conical flask (Corning®). This was placed on an open-air electric shaker (Amerex®) to allow complete mixing for 24 h, after which filtration was done using cheesecloth and then Whatman #1 filter papers. The filtrates were concentrated using a rotary evaporator (Rotavapor® R-210) at 53°C to evaporate off the ethanol. The remaining dry concentrated extract was weighed and the yield stored in a refrigerator at 5°C (Samsung RF22N9781SR). When needed, the dry concentrates were reconstituted separately in distilled water to make the required doses for the experiment (Solanki & Nagori, 2012; Sunmonu & Afolayan, 2013).

### 2.3.3 Animal models and their husbandry

Eight-week-old *Wistar* rats were obtained and then raised in the experimental animal house in the Faculty of Pharmacy at the Department of Pharmacology at Kampala International University Western Campus. The rats were kept for one (1) week for acclimatization and were maintained at room temperature (22-30°C) on standard rat pellets and water *ad libitum*. Animals were exposed to good husbandry practices through access to sufficient quality food, water *ad libitum*, exposure to 12-hour day/light cycle, adequate bedding, and sufficient spacing to minimize stress as previously described. After one week of acclimatization, each *Wistar* rat was assigned a random number, then grouped according to the study designs as described previously (Eteng et al., 2009; Kalange et al., 2020; Sunmonu & Afolayan, 2013).

### 2.3.4 Administration of the extract to the rats

During their 8<sup>th</sup> week of life, the rats were administered by gastric intubation with 2ml of distilled water (control), 200mg/kg, or 300mg/kg body weight of extract once daily between the hours of 8:00-10:00 am for 5 weeks. The weights were measured once weekly between the hours of 7:00-8:00 am for 5 weeks on days 8, 15, 22, 29, and 36. For kidney weight, morphology, biochemical tests, CD4 cell counts and histology experiments the rats were administered *p.o* with the 2ml distilled water or the extract (200 or 300mg/kg body weight) once daily between the hours of 8:00-10:00 am for 5 weeks before the samples were removed from the rats on day 36 between the hours of 8:00-10:00 am for testing in line with each objective similar to a previous method by (Eteng et al., 2009). The LD<sub>50</sub> of the extract was determined as 3000mg/kg body weight in the preliminary phases of our study, and following previous studies involving *Alafia barteri* extract on rats (Ishola et al., 2014, 2015; Lasisi et al., 2016; Sofidiya et al., 2014a); these formed the basis for the selection of the extract doses used in the study (200, and 300mg/kg body weight) as these were deemed to be very safe in acute, sub-chronic and chronic studies.

### **2.3.5 Gross anatomy experiments**

#### **2.3.5.1 Measurement of the rat body weight**

We placed a large plastic beaker (BrandTech®) on an electronic weighing scale (Kent Scientific®), tared the scale back to 0, placed the rat gently in the bowl, then noted the reading on the scale when the animal was still, this was taken as the weight of the animal (Atilade et al., 2018; Eteng et al., 2009; Hill et al., 2001).

#### **2.3.5.2 Measurement of the kidney weight and Assessment of kidney morphology**

Rats were dissected using previous methods, briefly, 24 hours after the last dose administration on day 36, the rats were anesthetized using thiopental sodium and sacrificed. The kidneys were harvested through a linea alba incision (Eteng et al., 2009; Kalange et al., 2020), and immediately after removing the kidneys, they were weighed using a sensitive electronic weighing machine (Kent Scientific®). After the weight was taken the kidneys were assessed visually for any gross morphology defects (Atilade et al., 2018; Eteng et al., 2009; Hill et al., 2001).

### **2.3.6 Hematological tests**

#### **2.3.6.1 Collection of blood samples**

Blood samples were collected using a previous method, briefly: after sacrificing the rats as described (Eteng et al., 2009), whole blood was collected by cardiac puncture from each of the rats into sterile red top plain vacutainer tubes for urea and creatinine analysis, and purple top EDTA coated vacutainers for CD4 cell counts. These were then left to stand for an hour to clot and serum samples separated from clot by centrifugation at 3,000 rpm for 10 minutes (CYAN CL008N). Sera obtained was used for the analysis of the different parameters in line with the objectives (Eteng et al., 2009).

#### **2.3.6.2 Kidney biochemical function tests**

##### **2.3.6.2.1 Quantification of the serum creatinine**

Transferred the serum using a disposable pipette and place serum into a plastic vial. Serum creatinine levels were determined using the chemical (picric acid) method; Jaffe reaction. The Jaffe reaction is the reaction of creatinine with alkaline picrate to form a colored compound; used to measure creatinine. Prepared Jaffe solution (NaOH and picric acid in equal volume). Each serum sample and a standard (50 µL) were gently mixed with 1000 µL of Jaffe working solution and incubated at 25 °C for 30 seconds. The orange-colored complex indicating maximum absorbance at 520 nm was measured using Stat Fax 3300 auto biochemistry analyzer. The intensity of the color is proportional to the concentration of the creatinine present in the serum sample and the results were expressed as mg/dl (Küme et al., 2017; Owen et al., 1954).

##### **2.3.6.2.2 Quantification of the serum urea**

Transferred the serum using a disposable pipette and place serum into a plastic vial. Serum urea was quantified using the chemical (diacetyl monoxime) method; Fearon reaction. The Fearon reaction is the reaction of urea with diacetyl monoxime to form a colored compound; used to measure urea. The hot acidic diacetyl monoxime in the presence of thiosemicarbazide was reacted with urea to produce red-colored complex with maxima at 525 nm. The intensity of the color is proportional to the concentration of urea in the sample and the results were expressed as mg/dl (Marsh, 1964; Park, 1986).

##### **2.3.6.3 Determination of the CD4 count**

The CD4+ lymphocytes were estimated by flow cytometry using the Cyflow automated cell counter (Partec, Germany). Fifty (50ml) of EDTA anticoagulated whole blood was mixed with 10µl of CD4+ PE anti-mouse CD4 antibody (Partec, Germany) in a test tube. The mixture was incubated in the dark chamber for 15 min at room temperature of 22 - 30°C. During incubation, the content of the tube was stirred every 5 minutes. Eight hundred microlitres of buffer solution were added, mixed, and plugged into the counter. After counting the CD4+ cells, monocytes and noise were separated gated and the result was recorded (Ekaidem et al., 2010).

### **2.3.7 Histological experiments**

#### **2.3.7.1 Collection of the kidney tissue samples**

Kidney tissue samples were collected using a previous method, briefly: after sacrificing the rats as described by (Eteng et al., 2009), and accessing/harvesting the kidneys through a linea alba incision (Kalange et al., 2020), the kidneys were dissected to separate the right cortices that were placed in 10% neutral buffered formalin fixative at room temperature (22- 30°C) for 24 hours, to be preserved for routine histological processing (Hill et al., 2001).

#### **2.3.7.2 Tissue Fixation, embedding, and sectioning**

After 24 hours of fixation, the kidney cortices were washed with 70% ethanol, put in a plastic tissue cassette, and processed in a paraffin automated tissue processor (Histokinette-SLEE MAINZ, MTP type) overnight.



The impregnated kidney tissues were then removed from the tissue cassettes and embedded in a molten wax bath on the tissue embedding center, then allowed to cool on a cold plate of embedding center. Excess wax was trimmed away using a blade and the cold block was then mounted to the Rotary microtome (SLEE MAINZ, CUT4062 model) for transverse sectioning into 4 $\mu$  sections onto salinized microscope slides. The sections were processed further until they were made ready for manual staining using hematoxylin and eosin (H and E) using standard protocols (Burke, 1968; Fischer et al., 2008; Slaoui & Fiette, 2011).

### **2.3.7.3 Haematoxylin and eosin (H & E) staining technique on kidney cortex tissue sections**

Deparaffinized the section by flaming the slide on a burner and placed it in xylene. Hydrated the tissue section by passing through the decreasing concentration of alcohol baths and water (100%, 90%, 80%, 70%). Stained in hematoxylin for 4 minutes. Washed in running tap water until sections "blued" for 4 minutes. Differentiated in 1% acid alcohol (1% HCl in 70% alcohol) for 5 minutes. Washed in running tap water until the sections were again blue by dipping in an alkaline solution (ammonia water) followed by tap water wash. Stained in 1% Eosin Y for 10 minutes. Washed in tap water for 4 minutes. Dehydrated in increasing concentration of alcohol and cleared in xylene. Mounted in mounting media (Fischer et al., 2008; Slaoui & Fiette, 2011). The stained preparations from H and E were examined under a light microscope (Nikon Eclipse Ci, 104C type) with a mounted digital camera (Nikon digital sight DS, Fi 1) and attached to a computer with software (NIS-Elements F3.00, SP7; Build 547) for photography and data collection. Haematoxylin and eosin enabled studying the general morphology of the kidney cortical tissue (Ashburner, 1989; Fischer et al., 2008; Palladino et al., 2003).

### **2.3.8 Data analysis**

Statistical analysis, column bar and line graphic representations for the study were done using GraphPad Prism version 6. Data were presented as Mean  $\pm$  SEM with the following tests: the one-way analysis of variance (ANOVA), Tukey posthoc test (to compare all groups with unequal variances) followed by *post-hoc* Dunn's test, two-way ANOVA, paired and unpaired t-test. A  $p < 0.05$  was considered significant, all done on parameters of body weight, kidney weight, blood creatinine, and urea, and CD4 cell count on 5 rats in each treatment group using standard statistics by (By et al., 1994; Muthén & Muthén, 2012). Histological data were obtained by photomicrographic analysis of kidney tissue sections from 5 rats in each treatment group, and the kidney histological findings were graphically represented as grouped stacked bars.

## **3.0 Results**

### **3.1 Body weight of rats**

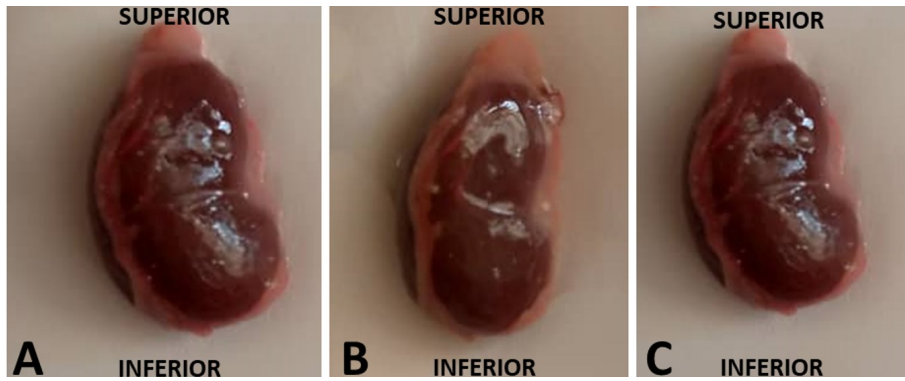
During the first week of the study, the rats weighed 115g and treatment with 200mg/kg unlike 300mg/kg that decreased the weight to 105g, did not change the weight; however, there was no significant change ( $P > 0.05$ ) in weight between the control group and 200, 300mg/kg; or between 200mg/kg and 300mg/kg. During the second week, the rats within the control group weighed 121g and treatment with 200mg/kg group did not change the weight while those treated with 300mg/kg decreased it to 109g; there was no significant change ( $P > 0.05$ ) in the weights of the two groups compared to the control or between those of 200mg/kg and 300mg/kg. The rats weighed 137g during the 3<sup>rd</sup> week with no increment in weight when treated with 200mg/kg. However, treatment with 300mg/kg reduced the weight by 8.7% but there was no significant difference ( $P > 0.05$ ) in the weights of the animals exposed to 200 and 300mg/kg in comparison with the control or 200mg/kg against 300mg/kg. Between weeks 3 and 4 the rats maintained a similar weight of the control group but those treated with 200 and 300mg/kg led to increased weight from 137 to 166g; 115 to 160g in the 200 and 300mg/kg-treated groups respectively. The increased weight in the two treatment groups showed significant differences in the weights ( $P = 0.0005$ ,  $P = 0.0028$ ) respectively compared to the control group, but with no significant differences ( $P > 0.05$ ) between the weights in the two treatment groups. Although the animals in the control group maintained their weight between weeks 4-5, the treatment group animals lost their weight by 10.3% and 19% in 200 and 300mg/kg groups respectively, this resulted in the weights for the treated animals being significantly indifferent ( $P > 0.05$ ) compared to the control and each other (Figure 2A, Table 1).

### **3.2 Gross morphology of the kidney**

There were no gross morphological changes in the kidney of the Wistar rats in the 200 and 300mg/kg groups compared to the control (Figure 1).

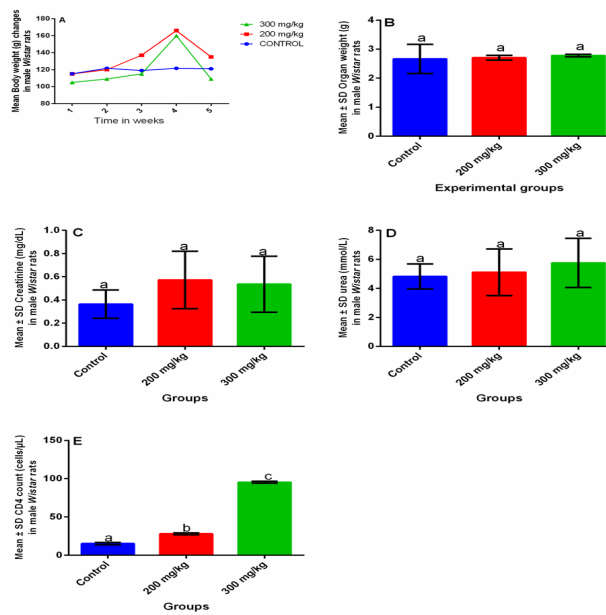
### **3.3 Weight of the kidney**

The kidney weight of the rats in the control group was 2.7g; treatment with 200 and 300mg/kg showed no increment in weight and therefore no significant difference in the weight of the treatment groups ( $P > 0.05$ ) against the control; as well as between the treatment groups (Figure 2B, Table 2).



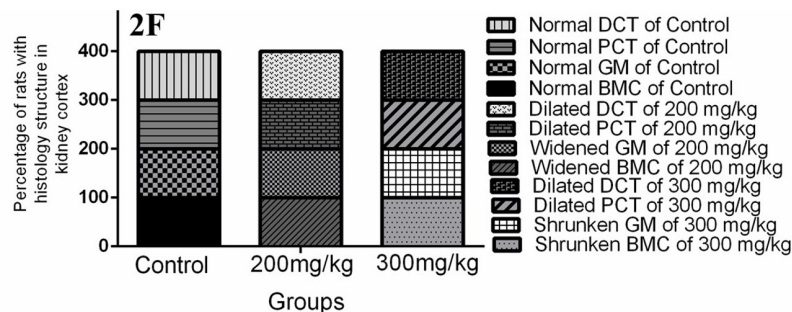
**Figure 1:** Effect of treatment with *Alafia barteri* extract in adult male Wistar rats on gross morphology of the kidney

**KEY:** A= Control; B= 200mg/kg; C= 300mg/kg body weigh



**Figure 2:** Effect of treatment with *Alafia barteri* extract in adult male Wistar rats

A= Line graph showing the effect on the body weight in 12-week-old adult rats; Bodyweight (y-axis) plotted against doses 0, 200, and 300 mg/kg body weight. Generally, body weights increased by week 4 in the 200 mg/kg and 300 mg/kg however no significant differences were found with the control group. Figures B-E show the effect on the kidney weight, blood creatinine, urea, and CD4 count respectively



**Figure 2F:** Grouped stacked bar graphs showing the effect of treatment with *Alafia barteri* extract on the histomorphology of the kidney cortex of 13-week-old adult Wistar rats. Histomorphological structures in the kidney cortex (y-axis) plotted against extract doses 0, 200, and 300 mg/kg body weight. BMC= Bowman's capsule; GM= Glomerulus; PCT= Proximal convoluted tubule; DCT= Distal convoluted tubules. Red color indicates severity 208x257mm (300 x 300 DPI)

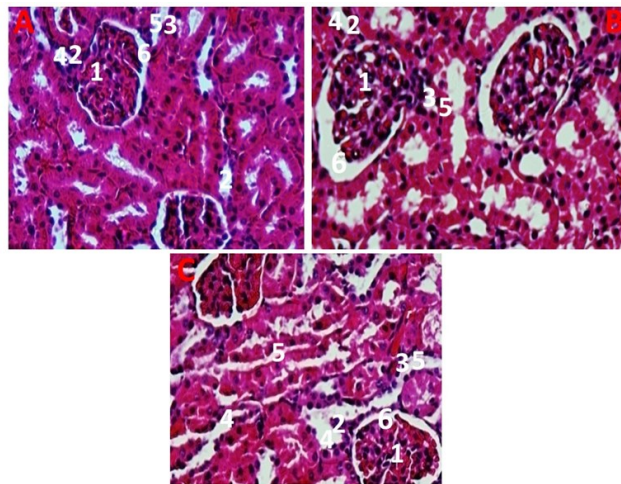
**Table 1:** Multiple comparisons on body weight of 9-13-week old adult Wistar rats following treatment with Alafia barteri extract.

Tukey's multiple comparisons tests	Adjusted P-value				
	Time (Weeks)				
	1	2	3	4	5
Concentration (mg/kg)					
CONTROL vs. 200	0.9998	0.9885	0.2425	0.0005	0.4204
CONTROL vs. 300	0.6289	0.4944	0.9306	0.0028	0.5275
200 mg/kg vs. 300	0.6402	0.5835	0.124	0.8509	0.0567

**Table 2.** Multiple comparisons on organ weight, blood creatinine levels, urea concentration, and a CD4 count of 13-week old adult Wistar rats following treatment with Alafia barteri extract.

Tukey's multiple comparisons tests	Kidney weight	Creatine	Urea	CD4
	Adjusted P-value			
CONTROL vs. 200 mg/kg	0.9751	0.3019	0.9442	<0.0001
CONTROL vs. 300 mg/kg	0.806	0.4295	0.5717	<0.0001
200 mg/kg vs. 300 mg/kg	0.9092	0.961	0.7631	<0.0001

**KEY:** CD4= Cluster of Differentiation



**Figure 3:** Changes in renal tissues following exposure to Alafia barteri in male Wistar rats. Photomicrographs (transverse sections), x100 magnification. A = control group, B = 200 mg/kg, C = 300 mg/kg. 1= Glomerulus; 2=Proximal convoluted tubule; 3= distal convoluted tubule; 4= distal convoluted tubule lumen; 5= proximal convoluted tubule lumen. Changes were mainly in the renal corpuscle. 254x190mm (96 x 96 DPI)

### 3.4 Blood creatinine levels

The blood creatinine level of the rats in the control group was 0.364mg/dl; treatment with 200 and 300mg/kg increased the levels to 0.572mg/dl and 0.536mg/dl respectively although this did not result in a significant difference of the creatinine levels of the treatment groups ( $P > 0.05$ ) against the control; as well as between the treatment groups (Figure 2C, Table 2).

### 3.5 Blood urea levels

Although there was a slight increment in the blood urea concentration from 4.882mmol/L → 5.116mmol/L → 5.76mmol/L in the: control → 200mg/kg → 300mg/kg, there was no significant difference ( $P > 0.05$ ) in the blood urea levels of either of the two treatment groups against the control or blood urea levels of 200mg/kg against the 300mg/kg groups (Figure 2D, Table 2).

### 3.6 CD4 count

There was a sharp increase in the CD4 count from 15.26 cells/mm<sup>3</sup> of the control to 28, and 95.48 cells/mm<sup>3</sup> of 200, and 300mg/kg groups and this was associated with significant differences ( $P < 0.0001$ ,  $P < 0.0001$ ) in the CD4 count of 200 or 300mg/kg-treated animals against those of the control; additionally there was a significant difference in the CD4 counts of 200 and 300mg/kg (Figure 2E, Table 2).

### 3.7 Histology of the kidney cortex

The normal rats had the expected normal structure of Bowman's capsule, glomerulus, proximal and distal convoluted tubules. Treatment with 200mg/kg resulted in a widened Bowman's capsule and glomerulus with a more dilated proximal and distal convoluted tubules associated with a wide lumen of the tubules within the renal cortex; treatment with 300mg/kg showed shrunken glomerulus and widened proximal and distal convoluted tubules with enlarged lumens of the tubules (Figure 3A, B).

## Discussion

Treatment of the rats with the extract for 1, 2, 3, or 5 weeks was not associated with a modification of body weight, but four-weeks' treatment was associated with a dose-independent gain in body weight. Oral ingestion of *Alafia barteri* extract does not disrupt the physiology of body structures, improves their function, and does not modulate body weight of the rats (S. A. Adelakun et al., 2018), this is in line with the results of our study where the weight of the animals was not modulated, except the gain in body weight observed during the fourth week of the study. The gain in body weight during the fourth week of the study is in agreement with (S. A. Adelakun et al., 2018) that the extract can improve body function (S. A. Adelakun et al., 2018) and with (Atilade et al., 2018, 2019) that sub-acute (6 weeks) ingestion of the herb increases body weight (Atilade et al., 2018, 2019). However, our findings are contrary to those in a previous study where a similar dose (31–327 ppm) of the ethanolic extract of *Alafia barteri* was shown to be toxic to brine shrimp larvae (*Artemia salina*) (Lasisi et al., 2016), this is because, despite its use in toxicity testing of mammals, brine shrimp (crustacean) results are not always representative of mammals due to the different anatomical and body physiological make-up (Vanderklift & Ponsard, 2003). In conclusion, the extract is not toxic to bodyweight but in some circumstances, it is associated with a gain in body weight of *Wistar* rats, however, the infrequent gain in body weight due to the extract needs further investigation.

The extract was not toxic to the gross morphology and did not modify the kidney weight of the rats in concurrence with (S. A. Adelakun et al., 2018), however, our extract caused histological distortion of kidney cortical structures (Bowman's capsule, glomerulus, proximal and distal convoluted tubules) in contradiction to previous studies (S. A. Adelakun et al., 2018) and (Atilade et al., 2018) that showed that oral ingestion of the extract as non-toxic to kidney histology (S. A. Adelakun et al., 2018; Atilade et al., 2018). In this case, our extract is harmful to the kidney cells as was the case to brine shrimp larvae (Lasisi et al., 2016), but neither safe nor ameliorative to the defective kidney cells (s), contrary to findings by (S. A. Adelakun et al., 2018; Atilade et al., 2018). These findings are in agreement with findings from previous studies, which found that despite their numerous medicinal uses, the plants of family *Apocynaceae* to which *Alafia barteri* belongs contain toxic compounds (pro-toxic dehydropyrrolizidine alkaloids) (Colegate et al., 2016; Liu et al., 2013) and herbs contain heavy metals, which when consumed in raw herbs could pose major health risks to mammals (Ssempijja et al., 2020) including injury to the kidneys (Musabayane, 2012; Olujimi et al., 2014).

The extract was associated with normal biochemical markers of kidney function (blood creatinine and urea). This means that despite causing injury to the kidney cortical cells, the extract did not cause impairment of kidney function or kidney disease (Yadav et al., 2014). This finding concurs with (Musabayane, 2012) that plant extracts could be harmful to kidneys but disagrees with them on the fact that the resulting harm causes impairment of renal function. Renal cytochromes P450 and peroxidases are involved in the metabolism and activation of phytochemicals such as alkaloids (ellipticine) in *Apocyanaceae*; the integrity of the enzymatic systems determines the pharmacological efficiency, genotoxic side-effects, excretion of this herb, as well as the integrity of the kidneys themselves (Stiborova et al., 2010). Injury to the rat renal cortical cells was not associated with impairment of renal function or kidney disease because of the intact renal enzymatic systems that were able to metabolize, excrete and reduce the side-effects of the herb (Stiborova et al., 2010). The ethanolic extract of *Rauwolfia vomitoria*, a different variety of *Apocynaceae* compared to that used in our study (*Alafia barteri*; *Apocynaceae*), led to impairment of the renal biochemical indices (elevated serum creatinine and urea), with resultant abnormal kidney function (Eteng et al., 2009), but this is not surprising because extracts from the same plant but obtained from different parts of that plant such as leaves and roots can show different effects on kidney function tests; and different varieties of the same family of plants can as well show differences in renal physiology (Eteng et al., 2009; Musabayane, 2012). In conclusion, our extract causes injury to the renal cortical cells but does not cause impairment of kidney function or kidney disease.



Ingestion of the ethanolic extract of *Alafia barteri* causes a dose-dependent increase in the CD4 cell count associated in line with studies that have associated *Apocynaceae* with modulation of CD4 cells in mice (Santos et al., 2018), an increase in CD4 counts in HIV patients (Maes & Maes, 2015), showing the impact of *Apocynaceae* plants on the CD4 cells, especially during the management of certain ailments (Maes & Maes, 2015; Santos et al., 2018). Our findings and those by (Maes & Maes, 2015; Santos et al., 2018) are in confirmation of the fact that *Alafia barteri* leaf extract is an immune booster used for different pharmacological properties as an antispasmodic, antiplasmodial, antifungal, antibacterial, anti-inflammatory, reduction of edema, analgesia through inhibition of acetic acid, antiproliferative through cytotoxicity of cancer cells in rats (Hamid, Aiyelaagbe, Negi, et al., 2017; Sofidiya et al., 2014b), antiproliferative through suppressing the viability of the hepatic, breast and leukemic cancer cell lines (Hamid, Aiyelaagbe, Kaneez, et al., 2017), alkaloid inhibition of growth against human neoplastic cells (Liu et al., 2013), and antioxidation to protect cells and tissues against detrimental effects of reactive oxygen species and other free radicals (Owolabi et al., 2018). Although none of the above pharmacological properties was histo-protective to the kidney cortex contrary to (S. Adedokun et al., 2018; Owolabi et al., 2018) but was protective to the gross morphology of the kidney, renal physiology and was non-toxic to the bodyweight of *Wistar* rats in agreement with (S. Adedokun et al., 2018; Owolabi et al., 2018). The molecular mechanism (s) through which *Alafia barteri* protects body tissues and processes of our study is not adequately known (Mahomoodally, 2013), our study shows that the extract works via the improvement in the status of the immune system through increasing the numbers of CD4 (T-helper) cells. These leucocytes will then be recruited in cell-mediated immune responses of the innate and adaptive immune systems to protect the body against infections, illnesses, and pathogens or preventing their growth (Li & Flavell, 2008), through the production of T-cell cytokines in response to specific antigen stimulation, help for antibody production, coordinating immune responses, lysis of infected target cells with type 2 histocompatibility antigens, serve as a cellular receptor for antigens, among others. The CD4 cell count gives an indication of the health status of the immune system and the ability to fight against pathogens, infections and illnesses (Bodhade et al., 2011; Yarchoan et al., 1991).

In conclusion, the extract improves the health status of the immune system and the ability to fight against pathogens, infections, and illnesses. It is important to note that the mechanism (s) and phytochemical compound (s) that lead to the increase of the CD4 cells was not established in our study, and these need to be explored.

## Conclusion

The present study has shown that when the ethanolic extract of *Alafia barteri oliver* (*Apocynaceae*) is used in therapeutic doses, it distorts the kidney histo-morphology but is safe to kidney gross morphology, kidney function, body weight and boosts the immune system (CD4 cell count increases) of *Wistar* rats.

## Recommendation

In the human context the study informs us that the extract of *Alafia barteri oliv* is safe form phytotherapy, and is of value in boosting the immune system (CD4 cells), thus could be used to develop drug formulations that are safe and pharmacologically important in various ailments. However, there is a need to further explore the cause and clinical value of the infrequent gain in body weight that is associated with the oral ingestion of *Alafia barteri* extract. We recommend that the mechanism (s) and phytochemical compound (s) that lead to the increase of the CD4 cells be explored.

## Limitations of the Study

There are slight gender differences in physiological functions and toxicological results in *Wistar* rats; furthermore, information from female *Wistar* rats would offer further insights on any toxicological effects which may be gender-related (Foucaud et al., 2010; Grotewiel et al., 2005; Iris Christine Howlett, 2013). However, we used only male *Wistar* rats to ensure uniform interpretation and reproducibility of results.

## Abbreviations

CD4	Cluster of differentiation
LD <sub>50</sub>	Lethal dose, 50%
H & E	Hematoxylin and Eosin
NaOH	Sodium hydroxide

## Declarations

## Acknowledgment

The authors wish to appreciate the practical intellectual advice offered by colleagues who are not on the authorship list. Also, we acknowledge the support offered by the local herbalists in the Bushenyi municipality through sharing of knowledge regarding the local herbs, thus helping in the choosing of this herbal plant amongst many other plants we would have sampled, thus keeping production costs low.

## Competing Interests

Authors declare no competing interests exist.

## Ethics approval and consent to participate

Ethical approval was acquired from the Scientific and Ethics review committee of Kampala International University Western Campus.

Consent to participate did not apply to this study.

## Funding

Not Applicable

## Data Availability

Data files can be accessed at <https://figshare.com/s/0a842177a881130df5a2>

## Consent for publication

Not applicable.

## References

- Adelakun, S. A., Ogunlade, B., & Omotoso, O. D. (2018). Spermatogenesis and Steroidogenesis Functions of Rat Testis Following Exposure to Alafia barteri Leaf Extracts. *Jordan Journal of Biological Sciences*, 11(5), 585–590.
- Adelakun, S., Ogunlade, B., & Omotoso, O. (2018). Histomorphological responses to aqueous crude leaf extract of Alafia barteri on prefrontal cortex, heart, kidney, liver and testis of adult male Sprague-Dawley rats. *European Journal of Biological Research*, 8(2), 105–111. <https://doi.org/10.5281/zenodo.1284554>
- Ashburner, M. (1989). *Drosophila. A laboratory Handbook* (Vol. 1).
- Atilade, A. O., Ruth, F. A., Magret, E. O., Joseph, D. B., Adetunji, O. W., Ebiwonjumi, A. S., & Okeniran, O. S. (2019). Diabetes and its Complication : Aqueous Leaf Extract of Alafia barteri Maintained the Pancreatic and Gastric Integrity in Allosan Induced Diabetic Rats (*Rattus Novergicus*). *Endocrinology & Metabolic Syndrome*, 8(2), 1–5.
- Atilade, A. O., Victoria, O., Joseph, D. B., & Segun, E. A. (2018). *Aqueous Leaf Extract of Alafia Barteri Maintained Renal Integrity in Diabetic Wistar Rats*. 2(1), 1–8.
- Bodhade, A. S., Ganvir, S. M., & Hazarey, V. K. (2011). Oral manifestations of HIV infection and their correlation with CD4 count. *Journal of Oral Science*, 53(2), 203–211. <https://doi.org/10.2334/josnusd.53.203>
- Burke, D. (1968). A modification for the combined staining of cells and fibers in the nervous system. *The American Journal of Medical Technology*, 34(11), 667–670.
- By, S., Miles, M. B., & Michael, A. (1994). Qualitative Data Analysis: An Expanded Sourcebook. *Journal of Environmental Psychology*, 14(4), 336–337. [https://doi.org/10.1016/S0272-4944\(05\)80231-2](https://doi.org/10.1016/S0272-4944(05)80231-2)
- Colegate, S. M., Gardner, D. R., Betz, J. M., Fischer, O. W., Liede-Schumann, S., & Boppré, M. (2016). Pro-toxic 1,2-Dehydropyrrolizidine Alkaloid Esters, Including Unprecedented 10-Membered Macrocyclic Diesters, in the Medicinally-used Alafia cf. caudata and Amphineurion marginatum (Apocynaceae: Apocynoideae: Nerieae and Apocyneae). *Phytochemical Analysis*, 27(5), 257–276. <https://doi.org/10.1002/pca.2624>
- Ekaidem, I. S., Atangwho, I. J., Akpan, H. D., Usuh, I. F., Etim, O. E., & Ebong, P. E. (2010). Effects of ethanol extract of Azadirachta indica leaves on some immunological and haematological parameters of diabetic Wistar rats. *African Journal of Pharmacy and Pharmacology*, 4(3), 104–108.
- Eteng, M. U., Ibekwe, H. A., Abolaji, A. O., Okoi, A. I., Onwuka, F. C., & Osuchukwu, N. C. (2009). Effect of Rauwolfia vomitoria Afzel (Apocynaceae) extract on serum amino transferase and alkaline phosphatase activities and selected indices of liver and kidney functions. *African Journal of Biotechnology*, 8(18), 4604–4607. <https://doi.org/10.5897/AJB2009.000-9422>

Fischer, A. H., Jacobson, K. A., Rose, J., & Zeller, R. (2008). Hematoxylin and Eosin Staining of Tissue and Cell Sections. *Cold Spring Harbor Protocols*, 2008(6), pdb.prot4986-pdb.prot4986. <https://doi.org/10.1101/pdb.prot4986>

Hamid, A. A., Aiyelaagbe, O. O., Kaneez, F., Luqman, S., & Negi, A. S. (2017). Isolation, characterization and antiproliferative evaluation of constituents from stem extracts of *Alafia barteri* Oliv. Hook. F. *Medicinal Chemistry Research*. <https://doi.org/10.1007/s00044-017-2033-4>

Hamid, A. A., Aiyelaagbe, O. O., Negi, A. S., Luqman, S., & Kaneez, F. (2017). New Triterpenoids from the Leaves of *Alafia barteri*. *Chemistry of Natural Compounds*, 53(6), 1075–1079. <https://doi.org/10.1007/s10600-017-2204-z>

Hill, C., Flyvbjerg, A., Rasch, R., Bak, M., & Logan, A. (2001). *Transforming growth factor- 2 antibody attenuates fibrosis in the experimental diabetic rat kidney*. 647–651.

Ishola, I. O., Agbaje, E. O., Adeyemi, O. O., & Shukla, R. (2014). Analgesic and anti-inflammatory effects of the methanol root extracts of some selected Nigerian medicinal plants. *Pharmaceutical Biology*. <https://doi.org/10.3109/13880209.2014.880487>

Ishola, I. O., Oreagba, I. A., OkekeOgochukwu, N., & Olayemi, S. O. (2015). Analgesic and anti-inflammatory actions of *Alafia barteri*: Involvement of monoaminergic, nitrenergic and opioidergic pathway. *Nigerian Quarterly Journal of Hospital Medicine*, 25(2), 118–123.

Kalange, M., Nansunga, M., Kasozi, K. I., Kasolo, J., Namulema, J., Atusiimirwe, J. K., Ayikobua, E. T., Ssempijja, F., Munanura, E. I., Matama, K., Semuyaba, I., Zirintunda, G., & Okpanachi, A. O. (2020). Antimalarial combination therapies increase gastric ulcers through an imbalance of basic antioxidative-oxidative enzymes in male Wistar rats. *BMC Research Notes*, 13(1), 230. <https://doi.org/10.1186/s13104-020-05073-7>

Küme, T., Sağlam, B., Ergon, C., & Rıza, A. (2017). *Evaluation and comparison of Abbott Jaffe and enzymatic creatinine methods : Could the old method meet the new requirements ? January*, 1–8. <https://doi.org/10.1002/jcla.22168>

Lasisi, A. A., Olayiwola, M. A., Balogun, S. A., Akinloye, O. A., & Ojo, D. A. (2016). Phytochemical composition, cytotoxicity and in vitro antiplasmodial activity of fractions from *Alafia barteri* olive (Hook F. Icon)-Apocynaceae. *Journal of Saudi Chemical Society*, 20(1), 2–6. <https://doi.org/10.1016/j.jscs.2012.05.003>

Li, M. O., & Flavell, R. A. (2008). TGF- $\beta$ : A Master of All T Cell Trades. *Cell*, 134(3), 392–404. <https://doi.org/10.1016/j.cell.2008.07.025>

Liu, L., Cao, J.-X., Yao, Y.-C., & Xu, S.-P. (2013). Progress of pharmacological studies on alkaloids from Apocynaceae. *Journal of Asian Natural Products Research*, 15(2), 166–184. <https://doi.org/10.1080/10286020.2012.747521>

Maes, D., & Maes, R. (2015). *Aspidosperma subincanum* II. Usefulness of uleine and ribonucleic fragments in the treatment of AIDS patients. *Revista Brasileira de Farmacognosia*, 25(1), 42–46. <https://doi.org/10.1016/j.bjp.2014.11.011>

Mahomoodally, M. F. (2013). Evidence - Based Complementary and Alternative Medicine Traditional Medicines in Africa : An Appraisal of Ten Potent African Medicinal Plants. *Evidence-Based Complementary and Alternative Medicine*, 2013, 1–10. <http://dx.doi.org/10.1155/2013/617459> (Accessed 02.03.2018)

Marsh, H. (1964). *the Urea*.

Musabayane, C. . (2012). The effects of medicinal plants on renal function and blood pressure in diabetes mellitus : review article. *Cardiovascular Journal Of Africa*, 23(8), 462–468. <https://doi.org/10.5830/CVJA-2012-025>

Muthén, L. K., & Muthén, B. O. (2012). *Mplus User 's Guide, ver 7*.

Olujimi, O. O., Bamgbose, O., Arowolo, T., Steiner, O., & Goessler, W. (2014). Elemental profiles of herbal plants commonly used for cancer therapy in Ogun State, Nigeria. Part I. *Microchemical Journal*, 117, 233–241. <https://doi.org/10.1016/j.microc.2014.06.022>

Owen, J. A., Iggo, B., Scandrett, F. J., & Stewart, C. P. (1954). The determination of creatinine in plasma or serum, and in urine; a critical examination. *Biochemical Journal*, 58(3), 426–437. <https://doi.org/10.1042/bj0580426>

- Owolabi, M., Ukpo, G., Oribayo, O., & Shode, F. (2018). Antioxidant Activity of Some Nigerian Medicinal Plants Used in Malaria Treatment. *Tropical Journal of Natural Product Research*, 2(1), 18–22. <https://doi.org/10.26538/tjnpr/v2i1.4>
- Palladino, M. J., Bower, J. E., Kreber, R., & Ganetzky, B. (2003). Neural Dysfunction and Neurodegeneration in *Drosophila* Na<sup>+</sup>/K<sup>+</sup> ATPase Alpha Subunit Mutants. *The Journal of Neuroscience*, 23(4), 1276–1286. <https://doi.org/10.1523/JNEUROSCI.23-04-01276.2003>
- Park, A. (1986). {Received January 23rd, 1986} {Accepted May 7th, 1986}. 41, 161–168.
- Santos, G. J. L., Oliveira, E. S., Pinheiro, A. D. N., da Costa, P. M., de Freitas, J. C. C., de Araújo Santos, F. G., Maia, F. M. M., de Moraes, S. M., & Nunes-Pinheiro, D. C. S. (2018). *Himatanthus drasticus* (Apocynaceae) latex reduces oxidative stress and modulates CD4<sup>+</sup>, CD8<sup>+</sup>, FoxP3<sup>+</sup> and HSP-60<sup>+</sup> expressions in Sarcoma 180-bearing mice. *Journal of Ethnopharmacology*, 220, 159–168. <https://doi.org/10.1016/j.jep.2017.09.043>
- Slaoui, M., & Fiette, L. (2011). Drug Safety Evaluation. In J.-C. Gautier (Ed.), *Methods in molecular biology* (Vol. 691, Issue 8). Humana Press. <https://doi.org/10.1007/978-1-60761-849-2>
- Sofidiya, M. O., Imeh, E., Ezeani, C., Aigbe, F. R., & Akindele, A. J. (2014a). Antinociceptive and anti-inflammatory activities of ethanolic extract of *Alafia barteri*. *Brazilian Journal of Pharmacognosy*. <https://doi.org/10.1016/j.bjp.2014.07.013>
- Sofidiya, M. O., Imeh, E., Ezeani, C., Aigbe, F. R., & Akindele, A. J. (2014b). Antinociceptive and anti-inflammatory activities of ethanolic extract of *Alafia barteri*. *Revista Brasileira de Farmacognosia*, 24(3), 348–354. <https://doi.org/10.1016/j.bjp.2014.07.013>
- Solanki, R., & Nagori, B. P. (2012). New Method for Extracting Phytoconstituents from Plants. *International Journal of Bio-medical and Advance Research*, 3(10), 770–774. <https://doi.org/10.7439/ijbar.v3i10.779>
- Sosef, M. S. M. & al. (2006). 1. *Alafia barteri*. In *Check-list des plantes vasculaires du Gabon Scripta Botanica Belgica* (p. 1). Royal Botanical Gardens. Kewscience. [http://wcsp.science.kew.org/acceptedRef.do;jsessionid=4553BF569F5EC8D6008D73309CB6A49D.kppapp06-wcsp?name\\_id=313727](http://wcsp.science.kew.org/acceptedRef.do;jsessionid=4553BF569F5EC8D6008D73309CB6A49D.kppapp06-wcsp?name_id=313727)
- Ssempijja, F., Eze, E. D., Tamale, A., Ewuzie, S. A., Matama, K., Ekou, J., Bogere, P., Mujinya, R., Musoke, G. H., Atusiimirwe, J. K., Zirintunda, G., Kalange, M., Lyada, J., Kiconco, R., Pius, T., Nandala, C., Kamugisha, R. M., Hamira, Y., Fernandez, E. M., & Musinguzi, S. P. (2020). *Consumption of Raw Herbal Medicines Is Associated with Major Public Health Risks amongst Ugandans. 2020(Cd)*.
- Stiborova, M., Moserova, M., Mrazova, B., Kotrbova, V., & Frei, E. (2010). Role of cytochromes P450 and peroxidases in metabolism of the anticancer drug ellipticine: Additional evidence of their contribution to ellipticine activation in rat liver, lung and kidney. *Neuroendocrinology Letters*, 31(SUPPL. 2), 26–35.
- Sunmonu, T. O., & Afolayan, A. J. (2013). Evaluation of Antidiabetic Activity and Associated Toxicity of *Artemisia afra* Aqueous Extract in Wistar Rats. *Evidence-Based Complementary and Alternative Medicine*, 2013, 1–8. <https://doi.org/10.1155/2013/929074>
- Teke, G. N., & Kuete, V. (2014). Acute and Subacute Toxicities of African Medicinal Plants. In *Toxicological Survey of African Medicinal Plants* (pp. 63–98). Elsevier. <https://doi.org/10.1016/B978-0-12-800018-2.00005-4>
- Yadav, P., Malik, D., Kumar, S., & Malik, V. (2014). *Effect of Elevated Creatinine Level in Blood Serum of Chronic Renal Failure Patients*. 6(1), 48–52.
- Yarchoan, R., Venzon, D. J., Pluda, J. M., Lietzau, J., Wyvill, K. M., Tsiatis, A. A., Steinberg, S. M., & Broder, S. (1991). CD4 count and the risk for death in patients infected with HIV receiving antiretroviral therapy. *Annals of Internal Medicine*, 115(3), 184–189. <https://doi.org/10.7326/0003-4819-115-3-184>

**Citation:** Okeniran OS, Adeyo OA, Adeyemi AO, Ssempijja F, Mariama S, Usman IM, Adesanya OA, Olakunle OA. “*Alafia Barteri* is Associated with Increased Cd4 Cell Counts and Distortion of the Nephrons in Male Wistar Rats” *SVOA Microbiology* 3:2 (2022) Pages 27-38.

**Copyright:** © 2022 All rights reserved by Okeniran OS., et al. This is an open access article distributed under the Creative Commons Attribution License, which permits unrestricted use, distribution, and reproduction in any medium, provided the original work is properly cited.